Common Cardiac Anomaly

Things we will cover: Fetal Circulation, Atrioventricular Septal Defect, Patent Ductus Arteriosis, Tetralogy of Fallot and Dextrocardia.

The majority of congenital heart defect are detected during antenatal screening. The diagnostic tools of choice are:

- Echocardiogram this allows us to view the heart in various cross section.
- Doppler can help to identify murmurs
- Chest x-ray (CXR) can be extremely useful as it can show sign of heart failure (enlarged heart).
- Electrocardiogram (ECG)

Depending on the severity of any of these conditions, if untreated they may lead to heart failure and need medical or surgical management. However, the exact management is beyond the scope of this project.

Fetal Circulation

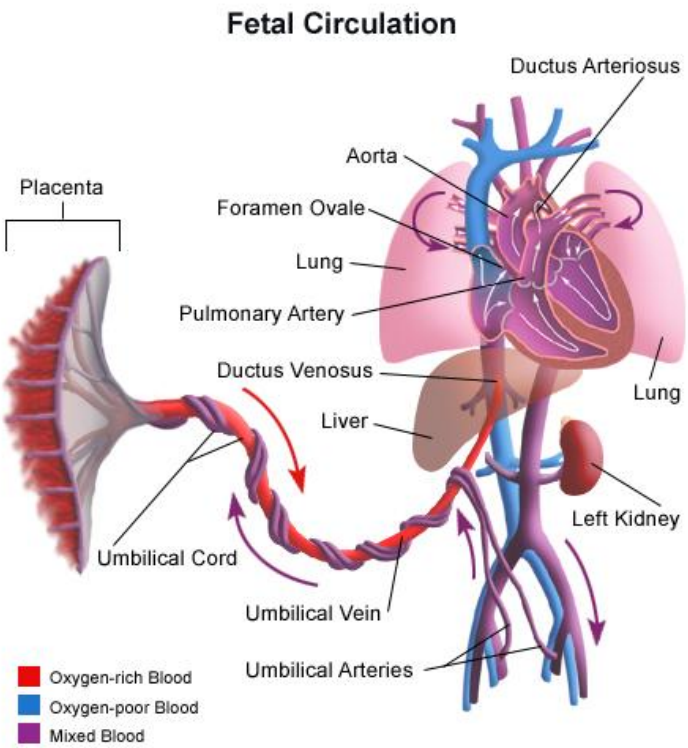

Figure 1: Illustration of the fetal circulation

http://www.stanfordchildrens.org/content-public/topic/images/67/281867.jpeg

Unlike the adult heart which has deoxygenated blood on the Right hand side and oxygenated on the left hand side; fetal circulation is slightly more complicated. The link below provides a systematic approach to understanding the fetal circulation.

http://www.youtube.com/watch?v=uwswhoKfkmM (see video)

Atrioventricular Septal Defect

Atrial Septal Defect (ASD)

ASD is essentially a hole between the two atriums. There are 2 main types Ostimum Secudum and Ostium Primum defects, they are named after the embryology and the way the septum forms (Figure 2).

Figure 2: A diagram showing Ostimum Secudum and Ostium Primum defects

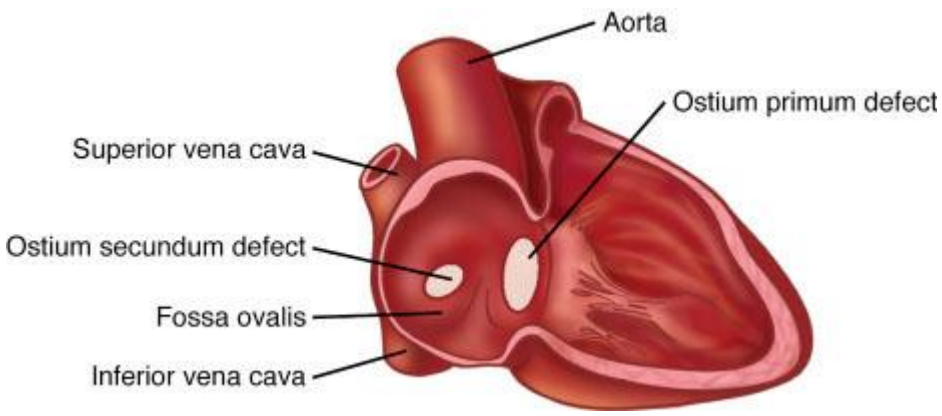

http://medical-dictionary.thefreedictionary.com/aortic+septal+defect

Ventral Septal Defect (VSD)

A VSD is a hole between the ventricles. This can be muscular (more common) which tends to heal as the muscle wall builds, or peri-membranous which is near the mitral valve.

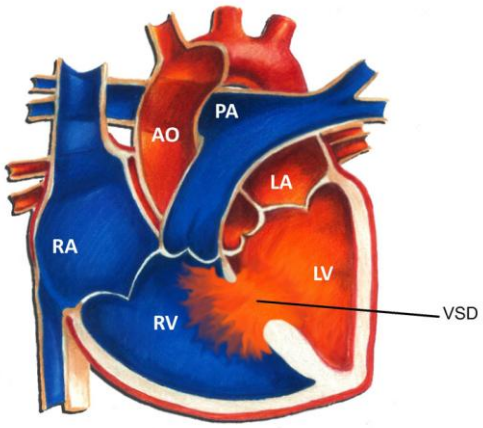

Figure 3: A diagram showing a VSD

http://www.urmc.rochester.edu/Encyclopedia/Content.aspx?ContentTypeID=90&ContentID=P01829

Patent Ductus Arteriosis (PDA)

The most commonly seen defect on the Neonatal Unit is a PDA, which is seen particularly in preterm babies. A PDA is when the Ductus Arteriosus fails to shut; it is patent in preterm babies due to the release of prostaglandin from the endothelium. If untreated it allows deoxygenated blood and oxygenated blood to mix and may lead to de-saturations. NSAIDs such as Indamethicin are helpful as they block the production of prostaglandin.

Figure 4: A diagram showing a PDA

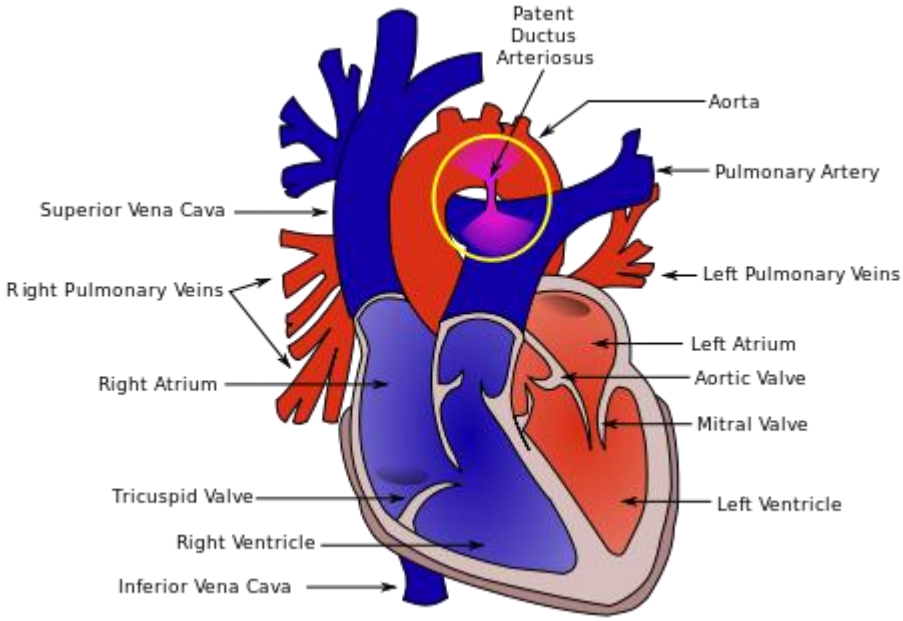

http://en.wikipedia.org/wiki/Patent_ductus_arteriosus#mediaviewer/File:Patent_ductus_arteriosus.svg

<u>Tetralogy of Fallot</u>

A combination of 4 abnormalities, which are:

1) Ventral Septal Defect (look above)

2) Right ventricular hypertrophy (enlarged right ventricular)

3) Overriding aorta (Aorta is positioned directly over the VSD instead of the Left Ventricle)

4) Pulmonary Stenosis (narrowing of the pulmonary valve)

Inotrope

These alter the force of contraction of the heart; they can either be positive or negative.

Positive Inotropes increase the contractility of the heart; common examples are Catecholamine like Dobutamine, Dopamine and Adrenaline. They are particular helpful in acute heart failure to encourage the heart to pump.

Negative inotropes decrease the contractility of the heart; common examples are beta block and calcium channel block.

Dextrocardia

The Heart is on the RIGHT SIDE! (But it's on the wrong side)

A syndrome associated with dextrocardia is called Kartagener's. The syndrome includes DEXTROCARDIA, BRONCHOECTASIS and recurrent SINUSITIS.

Figure 5: A way to remember the signs associated with Kartagener's Syndrome.

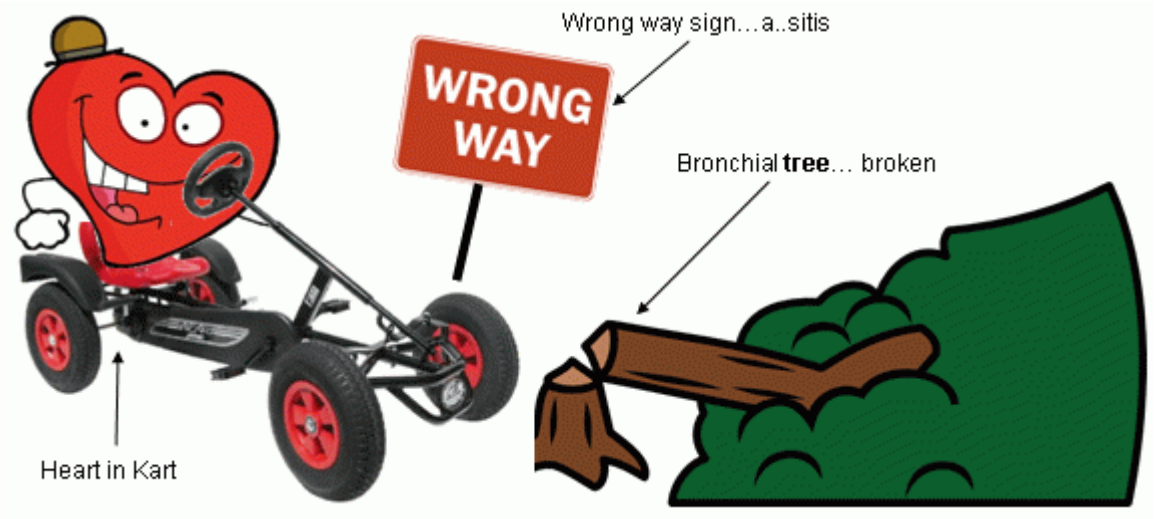

http://www.rewarm.co.uk/2012/05/kartageners-syndrome.htm